

## The diagnosis and management of necrotising fasciitis

Necrotising fasciitis was first described more than a century ago, however, its diagnosis still represents a challenge for clinicians and the condition carries a high mortality rate. The management of necrotising fasciitis requires prompt diagnosis, early surgical excision and proper coordination between the multidisciplinary team to achieve the best outcome for the patient. This paper reviews the diagnostic tools used in identifying necrotising soft tissue infections as well as examining the microbiology, management and prognosis.

*Authors:*  
Shady Hayek, Amir Ibrahim,  
Bishara Atiyeh

### Useful links

Recognising necrotising fasciitis

### References

1. Anaya DA, Dellinger EP. Necrotizing soft-tissue infection: diagnosis and management. *Clin Infect Dis* 2007; 44: 705–10.
2. Meleney F. Hemolytic Streptococcus gangrene. *Arch Surg* 1924; 9: 317–64.
3. Patino JF, Castro D. Necrotizing lesions of soft tissues: a review. *World J Surg* 1991; 15: 235–9.
4. Green RJ, Dafoe DC, Raffin TA. Necrotizing fasciitis. *Chest* 1996; 110: 219–29.
5. Dellinger EP. Severe necrotizing soft-tissue infections: multiple disease entities requiring a common approach. *JAMA* 1981; 246: 1717–21.
6. Fagan S, Spies M, Hollyoak M, Muller MJ, Goodwin CW, Herndon DN. Exfoliative and necrotizing diseases of the skin. In: Herndon DN (Ed). *Total Burn Care*, third edition. SAUNDERS-Elsevier, 2007: 554–562.

### INTRODUCTION

Necrotising soft tissue infections (NSTIs) were first described in 1871 as ‘hospital gangrene’ and they continue to carry a high mortality and morbidity rate<sup>[1]</sup>. Necrotising soft tissue infections are, as the name implies, infections that affect the soft tissue by causing necrosis. They spread along the fascial layers and can be either monobacterial or multibacterial in origin.

Although they are most often associated with surgical wounds, they can also occur in tiny cracks or breaks in the skin. They are considered surgical wound infections because the treatment involves surgical excision in addition to antibiotic administration, unlike non-necrotising soft tissue infections that require antibiotics only.

However, in the years since NSTIs were first discovered, many classifications and terms have been used to describe them

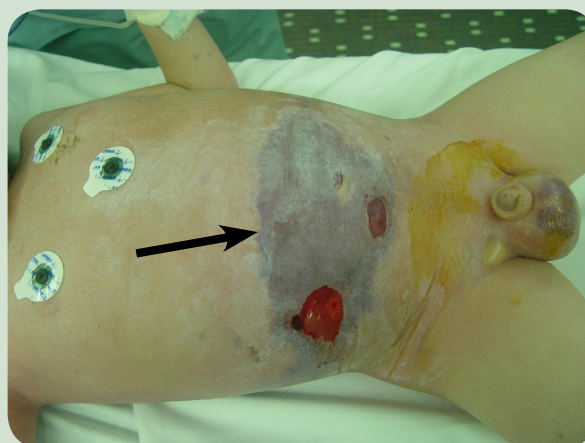
and there has been confusion surrounding their diagnosis and management<sup>[1–5]</sup>. This review will focus on the diagnosis, management and outcome of this condition.

### MICROBIOLOGY

NSTI is classified into two types based on the microbial pathogens involved and the immune status of the patient<sup>[6]</sup>.

#### Type 1

Type 1 occurs in about 20% of cases. Patients are typically healthy young individuals with an uncompromised immune system. These infections are usually monomicrobial in origin and caused mainly by group A Streptococcal infection or *Staphylococcus aureus*. A few cases will be caused by *Clostridium* species, and when associated



*Figure 1: A six-year-old boy presenting with septic shock and rapid deterioration. The arrow points to areas of skin necrosis. Note that even though the scrotal skin was bluish in colour, the supra-pubic area was normal.*

with myonecrosis they carry a very high mortality<sup>[7]</sup>. Recently, increased cases of monomicrobial NSTI caused by methicillin-resistant *Staphylococcus aureus* (MRSA) have been reported<sup>[8]</sup>.

Most cases of type 1 NSTI are associated with penetrating injuries or abscesses<sup>[6]</sup>.

### Type 2

Type 2 is the more common form of NSTI and is characterised by the presence of polymicrobial organisms of both aerobes and anaerobes. It usually occurs in people with compromised immune systems or those who are debilitated, especially those with diabetes mellitus or morbid obesity<sup>[6]</sup>.

Multiple organisms have been reported including gram-positive cocci, Enterococci, Gram-positive rods, Gram-negative organisms including *Klebsiella* and *Escherichia coli*, anaerobes and even fungi<sup>[1,7,9]</sup>. The presence of such a wide spectrum of organisms means that a range of antimicrobial medication is used initially, which can be adjusted according to the culture results<sup>[1,7,9]</sup>.

## DIAGNOSIS

Early diagnosis is the key to survival for patients with NSTI<sup>[1,7]</sup>. It is very important to differentiate necrotising from non-necrotising infections, as the former require surgical treatment as well as antibiotics and the latter only requires antibiotics<sup>[1]</sup>. In addition, non-necrotising soft tissue infections (like cellulitis and erysipelas) tend to occur in the skin layers themselves, whereas NSTIs tend to involve the fascial layers.

Diagnosis has been made more difficult by the different terms used to describe this condition<sup>[5]</sup>, but physical examination and taking an accurate patient history remain the mainstay for establishing a diagnosis.

People who are more likely to have NSTI include those with a history of self-injecting drug misuse (although NSTIs can occur with clinician-injected medication if the sterile technique has been violated), those with diabetes, a suppressed immune system and obesity<sup>[10-12]</sup>.

However, it has been repeatedly shown in larger studies that about 20% of people who develop NSTI do not have any of these precipitating factors and have an idiopathic aetiology<sup>[13-15]</sup>. It has been observed that these idiopathic cases mostly occur in people infected

Value	LRINEC points
<b>C-reactive protein (mg/dl)</b>	
<150	0
>150	4
<b>White blood cell (cells/cc)</b>	
<15	0
15–25	1
>25	2
<b>Haemoglobin level (g/dl)</b>	
>13.5	0
11–13.5	1
<11	2
<b>Sodium level (mmol/dl)</b>	
> 135	0
< 135	2
<b>Creatinine level (mg/dl)</b>	
< 6	0
> 6	2
<b>Glucose level (mg/dl)</b>	
< 180	0
> 180	1

Table 1 – LRINEC score variables.

with group A *Streptococcus*<sup>[1]</sup>, or MRSA<sup>[8]</sup>.

Initial symptoms to look for when examining a patient with suspected NSTI include pain, swelling, erythema and tachycardia. These will progress to discolouration, blister formation, eschar formation, crepitus, swelling outside the area of skin changes and pain out of proportion to the physical findings [Fig 1]<sup>[1]</sup>.

Of these symptoms, the authors find a disproportionate pain level to be a crucial indicator of NSTI. It has been found, however, that although these signs and symptoms are highly specific for NSTI, their sensitivity is low as they are present in only 10–40% of patients<sup>[16,17]</sup>.

In most cases, especially those caused by monomicrobial organisms, the progression of the signs and symptoms is rapid but conversely progression can be very slow, making accurate diagnosis challenging<sup>[1]</sup>.

Several diagnostic tools have been

## References

- Elliott D, Kufera JA, Myers RAM. The microbiology of necrotizing soft tissue infections. *Am J Surg* 2000; 179: 361–66.
- Miller LG, Perdreau-Remington F, Rieg G, Mehdi S, Perloth J, Bayer AS, Tang AW, Phung TO, Spellberg B. Necrotizing fasciitis caused by community-associated methicillin-resistant *Staphylococcus aureus* in Los Angeles. *N Engl J Med* 2005; 352: 1445–53.
- Endorf FW, Cancio LC, Klein MB. Necrotizing soft-tissue infections: clinical guidelines. *J Burn Care Res* 2009; 30: 769–75.
- Wall DB, Klein SR, Black S, de Virgilio C. A simple model to help distinguish necrotizing fasciitis from non-necrotizing soft tissue infection. *J Am Coll Surg* 2000; 191: 227–31.
- Wong CH, Khin LW, Heng KS, Tan KC, Low CO. The LRINEC (laboratory risk indicator for necrotizing fasciitis) score: a tool for distinguishing necrotizing fasciitis from other soft tissue infections. *Crit Care Med* 2004; 32: 1535–41.
- Singh G, Sinha SK, Adhikary S, Babu KS, Ray P, Khanna SK. Necrotising infections of soft tissues — a clinical profile. *Eur J Surg* 2002; 168: 366–71.
- Singh G, Ray P, Sinha SK, Adhikary S, Khanna SK. Bacteriology of necrotizing infections of soft tissues. *Aust NZ J Surg* 1996; 66: 747–50.
- Anaya DA, McMahon K, Nathens AB, Sullivan SR, Foy H, Bulger E. Predictors of mortality and limb loss in necrotizing soft tissue infections. *Arch Surg* 2005; 140: 151–7; discussion 158.
- Childers BJ, Potyondy LD, Nachreiner R, et al. Necrotizing fasciitis: a fourteen-year retrospective study of 163 consecutive patients. *Am Surg* 2002; 68: 109–16.

## References

16. McHenry CR, Piotrowski JJ, Petrinic D, Malangoni MA. Determinants of mortality for necrotizing soft-tissue infections. *Ann Surg* 1995; 221: 558–63; discussion 563–5.
17. Wong CH, Chang HC, Pasupathy S, Khin LW, Tan JL, Low CO. Necrotizing fasciitis: clinical presentation, microbiology, and determinants of mortality. *J Bone Joint Surg Am* 2003; 85: 1454–60.
18. Wong CH, Wang YS. The diagnosis of necrotizing fasciitis. *Curr Opin Infect Dis* 2005; 18: 101–6.
19. Yilmazlar T, Ozturk E, Alsoy A, Ozguc H. Necrotizing soft tissue infections: APACHE II Score, Dissemination, and Survival. *World J Surg* 2007; 31: 1858–62.
20. Struk DW, Munk PL, Lee MJ, Ho SG, Worsley DF. Imaging of soft tissue infections. *Radiol Clin North Am* 2001; 39: 277–305.
21. Wysoki MG, Santora TA, Shah RM, Friedman AC. Necrotizing fasciitis: CT characteristics. *Radiology* 1997; 203: 859–63.
22. Becker M, Zbären P, Hermans R, Becker CD, Marchal F, Kurt AM, Marre' S, Rüfenacht DA, Terrier F. Necrotizing fasciitis of the head and neck: role of CT in diagnosis and management. *Radiology* 1997; 202:471–6.
23. Yen ZS, Wang HP, Ma HM, Chen SC, Chen WJ. Ultrasonographic screening of clinically-suspected necrotizing fasciitis. *Acad Emerg Med* 2002; 9: 1448–51.
24. Majeski J, Majeski E. Necrotizing fasciitis: improved survival with early recognition by tissue biopsy and aggressive surgical treatment. *South Med J* 1997; 90: 1065–8.
25. Stamenkovic I, Lew PD. Early recognition of potentially fatal necrotizing fasciitis: the use of frozen-section biopsy. *N Engl J Med* 1984; 310: 1689–93.
26. Marshall JC, Maier RV, Jimenez M, Dellinger EP. Source control in the management of severe sepsis and septic shock: an evidence-based review. *Crit Care Med* 2004; 32: S513–26.
27. Wong CH, Yam AK, Tan AB, Song C. Approach to debridement in necrotizing fasciitis. *Am J Surg* 2008; 196: e19–24.

investigated that could be used in conjunction with clinical findings to help make a diagnosis as early as possible<sup>[18]</sup>, including laboratory studies, imaging studies and pathological examination<sup>[1]</sup>.

## LABORATORY STUDIES

Wall et al<sup>[10]</sup> retrospectively studied the admission variables for necrotising and non-necrotising infections and reported that a white blood cell count greater than 15,400 x 10<sup>3</sup> cells/cc, or a serum sodium level less than 135mmol/L were associated with a necrotising infection. When combined, these two parameters had a very high negative predictive value of 99%, indicating that they are a good tool for ruling out NSTI. However, the positive predictive value was very low (26%) indicating a very low specificity.

More recently, a laboratory score was created by Wong et al<sup>[17]</sup> to differentiate between necrotising and non-necrotising infections. Called the 'Laboratory risk indicator for necrotising fasciitis score' (LRINEC), it identified six independent laboratory variables associated with NSTI and gave each one of them a number of points [Table 1].

The summation of the points gives a score that ranges between 0–13. Three groups were then identified according to their risk for NSTI:

- If the score is 5 or less, then the probability of NSTI is low (less than 50%)
- If the score is 6 or 7, then the probability of NSTI is 50–75%
- If the score is 8 or more, then the probability of NSTI is very high (more than 75%).

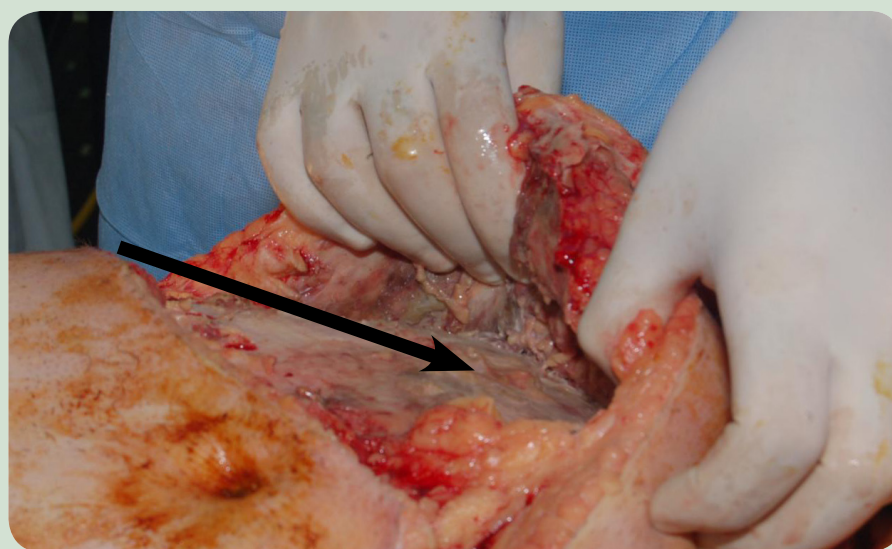
This tool was found to have a high positive predictive value (92%) and also a high negative predictive value (96%) for intermediate and high-risk groups<sup>[1, 11]</sup>.

Another test, the Acute Physiology, Age and Chronic Health Evaluation (APACHE II) score has been found to be non-specific for NSTI diagnosis, but helpful in predicting the prognosis for people with the infection<sup>[9, 19]</sup>. Yilmazlar et al<sup>[19]</sup> reported that patients who had an APACHE II score greater than 13 had an 86% mortality rate. All patients who died during the study had an APACHE II score of greater than 20.

All of these scores and laboratory parameters are supposed to aid in diagnosis, but it is important to remember that none of them replace the physical examination and assessment of an expert physician in making an early and accurate diagnosis<sup>[9]</sup>.

## IMAGING STUDIES

X-ray, ultrasound, computerised tomography (CT) scan and magnetic



**Figure 2:** A 40-year-old man who presented with rapidly extending NSTI of the genital and lower abdomen area. Note the fascial necrosis and infection despite normal overlying skin.



resonance imaging (MRI) have all been evaluated for their usefulness in diagnosing NSTI. X-ray can only show subcutaneous gas, which proves the presence of gas-producing bacteria such as *E. coli* or *Clostridium* species<sup>[1,20]</sup>. This means that X-ray is highly specific, but with low sensitivity, as it can miss many of the NSTIs caused by non-gas-producing bacteria.

CT scans have the advantage of being able to diagnose deep abscesses or other indicators of NSTI<sup>[20-22]</sup>. The major limitation of CT scans, however, is that they indicate the presence of NSTI by comparing the thickness of the fascial layer of an involved area with a non-involved area, rather than with an area exhibiting non-necrotising infection. Therefore, they do not distinguish between different infections<sup>[20-22]</sup>. Another disadvantage to using CT scans is that patients with suspected NSTI are often in shock and thus the use of intravenous contrast is contraindicated to avoid kidney damage<sup>[20]</sup>.

Ultrasound imaging has the same limitations as CT scans because it only compares the fascial layer<sup>[23]</sup>.

MRI scans do show oedema in the tissues but have a major limitation in that any contrast enhancement only highlights the edges of a necrotic area, not the necrosis itself<sup>[20]</sup>. In addition, MRI tends to overestimate necrosis because it cannot distinguish surrounding non-infectious oedema<sup>[20]</sup>.

General consensus in the literature is that if performing imaging studies for NSTI is going to delay treatment then they should not be performed due to the need for early surgery in these patients<sup>[1, 20]</sup>.

## PATHOLOGICAL EXAMINATION

Two studies looked at the outcome of frozen section pathological examination on a biopsy that included fascia and muscle layers<sup>[24, 25]</sup>. They reported a decreased mortality rate compared with historical controls, however, this might be due to the clinical suspicion that led to the early ordering of the frozen section biopsy rather than to the biopsy itself<sup>[1]</sup>.

In the authors' experience, if there is any doubt about the diagnosis, they will perform a small incision down to the fascial layer. If there is pus or necrosis then this confirms the diagnosis and fascial excision

proceeds [Fig 2]. This strategy has been very helpful in confirming clinical suspicion after frozen section or other imaging studies while reducing any delays to surgery.

## MANAGEMENT

Like any other surgical infection, the management of NSTI relies on three main principles:

- Source control
- Correct antimicrobial administration
- Organ support<sup>[1]</sup>.

NSTI is a perfect example and demonstrates the importance of immediate source control<sup>[26]</sup>. Without complete surgical excision of all infected tissues, mortality increases and may approach 100%<sup>[1, 27-29]</sup>.

Skin bridges and flaps should be avoided because they can be the source for expanding pockets of fasciitis and micro-abscesses<sup>[9]</sup>. Frequent monitoring and assessment of these patients postoperatively is mandatory as they may require another visit to the operating room for further debridement<sup>[9, 30]</sup>.

Concomitant with early and complete surgical excision is the administration of broad spectrum antibiotics to cover the wide range of possible infection-causing organisms<sup>[1]</sup>. Antimicrobials should include penicillin (for the Gram-positive bacteria), clindamycin (to inhibit the secretion of *Streptococcal* exotoxin), and a fluoroquinolone or an aminoglycoside (for the Gram-negative bacteria)<sup>[1, 9, 26, 31]</sup>.

With the increasing incidence of community-acquired MRSA and its involvement in mono or polymicrobial NSTI, the addition of vancomycin to the antimicrobial regimen is recommended until cultures show the absence of MRSA<sup>[1, 8, 32]</sup>.

The antimicrobial regimen should continue until organ system failure stops and the wound status improves. It should also be adjusted according to the final culture results<sup>[1]</sup>.

Organ support, whether respiratory, circulatory or any other system, should be continued until the system improves<sup>[1]</sup>. Nutritional and fluid support should not be neglected, particularly for patients with large open wounds<sup>[9]</sup>.

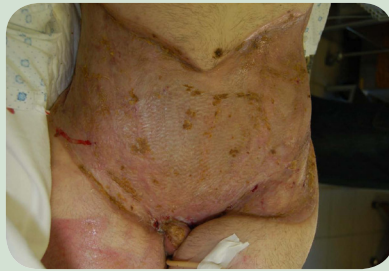Wound coverage should be carried out within a few weeks of improvement and is usually performed by applying

## References

28. Bilton BD, Zibari GB, McMillan RW, Aultman DF, Dunn G, McDonald JC. Aggressive surgical management of necrotizing fasciitis serves to decrease mortality: a retrospective study. *Am Surg* 1998; 64: 397-400; discussion 400-1.
29. Brandt MM, Corpron CA, Wahl WL. Necrotizing soft tissue infections: a surgical disease. *Am Surg* 2000; 66: 967-70.
30. Endorf FW, Klein MB, Mack C, Jurkovich GJ, Rivara FP. Necrotizing soft-tissue infections: differences in patients at burn centers and non-burn centers. *J Burn Care Res* 2008; 29: 933-8.
31. Stevens DL, Bryant AE, Hackett SP. Antibiotic effects on bacterial viability, toxin production, and host response. *Clin Infect Dis* 1995; 20: 515-7.
32. Wang R, Braughton KR, Kretschmer D, Bach TH, Queck SY, Li M, Kennedy AD, Klebanoff SJ, Peschel A, DeLeo FR, Otto M. Identification of novel cytolytic peptides as key virulence determinants for community-associated MRSA. *Nat Med* 2007; 13: 1510-4.
33. Akhtar S, Hasham S, Abela C, Phipps AR. The use of Integra in necrotizing fasciitis. *Burns* 2006; 32: 251-4.
34. Muangman P, Engrav LH, Heimbach DM, Harunari N, Honari S, Gibran NS, Klein MB. Complex wound management utilizing an artificial dermal matrix. *Ann Plast Surg* 2006; 57: 199-202.
35. Fernandez R, Griffiths R. Water for wound cleansing. *Cochrane Database of Systematic Reviews* 2008; 1 (art. no. CD003861). Available at: [http://www.mrw.interscience.wiley.com/cochrane/cdsysrev/articles/CD003861/pdf\\_fs.html](http://www.mrw.interscience.wiley.com/cochrane/cdsysrev/articles/CD003861/pdf_fs.html).
36. Hayek S, El Khatib A, Atiyeh B. Burn wound cleansing — A myth or a scientific practice. *Ann Burns Fire Disasters* 2010; 23: 19-24.

## References

37. Heinle EC, Dougherty WR, Garner WL, Reilly DA. The use of 5% mafenide acetate solution in the postgraft treatment of necrotizing fasciitis. *J Burn Care Rehab* 2001; 22:35–40.
38. De Geus HRH, Van der Klooster JM. Vacuum-assisted closure in the treatment of large skin defects due to necrotizing fasciitis. *Intensive Care Med* 2005; 31:601.
39. Bronchard R, de Vaumas C, Lasocki S, Jabbour K, Geffroy A, Kermarrec N, Montravers P. Vacuum-assisted closure in the treatment of perineal necrotizing skin and soft tissue infections. *Intensive Care Med* 2008; 34: 1345–7.
40. Riseman JA, Zamboni WA, Curtis A, Graham DR, Konrad HR, Ross DS. Hyperbaric oxygen therapy for necrotizing fasciitis reduces mortality and the need for debridements. *Surgery* 1990; 108: 847–50.
41. Korhonen K. Hyperbaric oxygen therapy in acute necrotizing infections with a special reference to the effects on tissue gas tensions. *Ann Chir Gynaecol Suppl* 2000; 89: 7–36.
42. Escobar SJ, Slade JB Jr, Hunt TK, Cianci P. Adjuvant hyperbaric oxygen therapy (HBO2) for treatment of necrotizing fasciitis reduces mortality and amputation rate. *Undersea Hyperb Med* 2005; 32: 437–43.
43. Norrby-Teglund A, Muller MP, Mcgeer A, Gan BS, Guru V, Bohnen J, Thulin P, Low DE. Successful management of severe group A streptococcal soft tissue infections using an aggressive medical regimen including intravenous polyspecific immunoglobulin together with a conservative surgical approach. *Scand J Infect Dis* 2005; 37: 166–72.
44. Cawley MJ, Briggs M, Haith LR Jr, Reilly KJ, Guilday RE, Braxton GR, Patton ML. Intravenous immunoglobulin as adjunctive treatment for streptococcal toxic shock syndrome associated with necrotizing fasciitis: case report and review. *Pharmacotherapy* 1999; 19: 1094–8.
45. Simmonds M. Necrotising fasciitis and group A streptococcus toxic shock-like syndrome in pregnancy: treatment with plasmapheresis and immunoglobulin. *Int J Obstet Anesth* 1999; 8: 125–30.
46. Purnell D, Hazlett T, Alexander SL. A new weapon against severe sepsis related to necrotizing fasciitis. *Dimens Crit Care Nurs* 2004; 23: 18–23.



**Figure 3: The same patient as shown in Figure 2, two months post coverage with split thickness skin grafts.**

split-thickness skin grafts<sup>[9]</sup> [Fig 3]. This can be performed in the hospital or the patient can be discharged to a rehabilitation centre until their nutrition is sufficient for the wounds to heal.

Skin replacement matrices have been recommended for covering these wounds due to the loss of the full thickness of the tissues from the skin all the way down to the muscle fascia<sup>[33, 34]</sup>.

However, the authors do not recommend this management protocol as despite the surgical excision and antibiotic administration, these wounds are never clean, and carry a high risk of infection until the matrix is well vascularised. After adequate control of the infection and when the patient's nutrition has been stabilised the wound can be closed by skin grafts.

Daily wound care should be performed, including daily cleansing, the application of topical agents and the use of appropriate dressings<sup>[9]</sup>. Some centres recommend the use of sterile saline, while others recommend using tap water. A Cochrane study into open wounds compared these two methods and found a reduced rate of wound infection when using tap water, probably due to its greater availability, which means it can be used more often<sup>[35, 36]</sup>.

The use of 5% mafenide acetate has been shown to facilitate early wound closure<sup>[37]</sup> and the authors use silver sulfadiazine 2% cream once or twice daily to help prepare a reasonably clean wound that is ready for closure.

Recent reports have recommended the use of vacuum-assisted closure, because it reduces the number of dressing changes, meaning less stress for patients and a lighter workload for nurses,<sup>[38, 39]</sup> but this technique still needs to be fully examined.

Hyperbaric oxygen therapy has also been recommended as an adjunct to treatment<sup>[40–42]</sup>, however, the evidence is still controversial and hyperbaric oxygen therapy use should not interfere with early and complete surgical excision<sup>[9]</sup>.

Other adjunctive techniques have been reported and small case series have been performed on the use of immunoglobulin G (IgG), plasmapheresis or activated protein C<sup>[43–46]</sup>. However, their role is still to be assessed in prospective controlled studies, meaning that there has yet to be conclusive evidence<sup>[1, 9]</sup>.

## PROGNOSIS

NSTI carries high mortality rate, which has been reported as approximately 46% in total<sup>[1]</sup>, although other reports cite a rate between 16–24%<sup>[14, 16]</sup>. Yilmazlar et al<sup>[19]</sup> have reported that an APACHE II score of 13 or greater and disease dissemination (the involvement of more than one anatomical areas of the human body, for example the upper extremities and the trunk) were found to be independently and associated with the mortality of patients with NSTI.

## CONCLUSION

In summary, NSTI is a serious infection that can cause death. It requires prompt diagnosis, and early and complete surgical excision in addition to broad spectrum antibiotic coverage and organ support.

This requires a team approach involving a critical care specialist, an infectious disease specialist, a surgeon, nurses, dietitians and rehabilitation specialists in order to achieve a satisfactory outcome.

## AUTHOR DETAILS

Shady Hayek MD is Assistant Professor, Plastic and Reconstructive Surgery, Hand Surgery, Burn Surgery, American University of Beirut-Medical Center, Lebanon;

Amir Ibrahim MD is Chief Resident in Plastic and Reconstructive Surgery, American University of Beirut-Medical Center, Lebanon;

Bishara Atiyeh, MD is Professor in Clinical Surgery, Plastic and Reconstructive Surgery, American University of Beirut-Medical Center, Lebanon and General Secretary, MBC Executive Editor, *Annals of Burns and Fire Disasters*.