

Aesthetic Surgery Journal

<http://aes.sagepub.com/>

Contouring of the Male Anterior Chest Following Bariatric Surgery and Massive Weight Loss

Bishara S. Atiyeh, Saad A. Dibo and Shady N. Hayek

Aesthetic Surgery Journal 2008 28: 688

DOI: 10.1016/j.asj.2008.07.008

The online version of this article can be found at:

<http://aes.sagepub.com/content/28/6/688>

Published by:



<http://www.sagepublications.com>

On behalf of:



[American Society for Aesthetic Plastic Surgery](#)

Additional services and information for *Aesthetic Surgery Journal* can be found at:

Email Alerts: <http://aes.sagepub.com/cgi/alerts>

Subscriptions: <http://aes.sagepub.com/subscriptions>

Reprints: <http://www.sagepub.com/journalsReprints.nav>

Permissions: <http://www.sagepub.com/journalsPermissions.nav>

>> [Version of Record](#) - Nov 1, 2008

[What is This?](#)

Contouring of the Male Anterior Chest Following Bariatric Surgery and Massive Weight Loss



Bishara S. Atiyeh, MD; Saad A. Dibo, MD; and Shady N. Hayek, MD

The male breast area can be difficult to treat following massive weight loss. In such patients, it is essential to correct the deformity without leaving disfiguring scars over the anterior surface of the chest, if possible. We suggest a surgical technique that involves a torsoplasty with concomitant nipple–areolar complex transposition, resulting in adequate male chest contouring with well hidden scars. (*Aesthetic Surg J* 2008;28:688–696.)

Patients who experience massive weight loss (MWL) present with bidimensional skin excess and are left looking “deflated,” with disfiguring skin laxity circumferentially around the torso, including the breasts, and redundant tissue on the upper arms, buttocks, and thighs, leading to poor social acceptance and quality of life.^{1–9} Severe dermatochalasis also may cause serious medical, functional, and psychological problems.^{1,2,5,10,11} To resolve these problems, body contouring is mandatory.

It is not possible to predict where body contouring deformities will materialize, because they may be present anywhere on the body.¹² However, the accurate classification of these deformities can assist the surgeon in operative planning. The Pittsburgh Rating Scale, for example, is useful in both classifying the individual deformities in a specific region and performing a comprehensive assessment for proper surgical planning.^{12,13} Satisfying results of body contouring procedures, however, are mainly dependent on resultant scars that respect the boundaries of aesthetic units^{14–17} and on the ability of the skin to retract, which is reduced in older patients.¹⁸ Moreover, the fact that the skin has been under tension for a prolonged period, and the frequent history of “yo-yo” dieting, leads to poor skin tone following MWL.⁵

In particular, contour deformities of the chest wall continue to present a significant challenge for surgeons.¹⁹ Following MWL, male breasts are one of the most disturbing body regions¹ and can be a difficult area to treat because of varying degrees of ptosis, nipple mal-

position, excessive parenchyma/fat, and loss of the inframammary fold, with a general loss of definition or shape.²⁰ Evaluation of the upper trunk following MWL should include a thorough analysis of the breast, chest, and the upper back. The degree of ptosis, the amount of breast parenchyma, and the location of the inframammary fold are all important aspects in evaluating the defined breast/chest region. In many cases, the lateral inframammary fold is displaced inferiorly.²⁰ The lateral chest, which is in continuity between the breast and the arms, often manifests with multiple skin rolls that start laterally and extend posteriorly. Horizontal excess around the circumference of the chest, vertical excess especially in the midaxillary line, and upper back rolls should all be evaluated.²⁰

The areola area is the major “aesthetic unit” in the male anterior chest; acceptable scar positioning in this area is very limited and is a problem if significant skin resection is needed.^{14,21–23} With greater weight loss, contouring of the male breast often requires a mastopexy along with lateral chest and back excision to remove excess tissue and maintain a flat-chested male physique, which in many cases results in significant scarring of the frontal chest wall (Figure 1).^{7,10,14,18,20,22,23} While at least some male patients are willing to accept these consequences, it must be stressed that the smallest possible frontal scars or, if possible, avoidance of noticeable scars on the chest wall by concealing them in locations such as the middle axillary line, is very important for patients who are concerned about the aesthetic appearance of the chest.^{14,24}

CASE REPORT

A 24-year-old male presented with severe dermatochalasis following bariatric surgery and MWL from 367.4 lbs (167 kg) and a body mass index (BMI) of 47 to 215.6 lbs (98 kg) and a BMI of 27.5. A circumferential lower trunk lift was performed first. The choice of a fleur-de-lys

Dr. Atiyeh is Clinical Professor of Plastic and Reconstructive Surgery in the Division of Plastic and Reconstructive Surgery, Department of Surgery, American University of Beirut Medical Center, Beirut, Lebanon. Dr. Dibo is a resident in the Division of Plastic and Reconstructive Surgery at the same institution. Dr. Hayek is a Fellow in the Department of Surgery, University of Iowa Carver College of Medicine, Iowa City, IA.

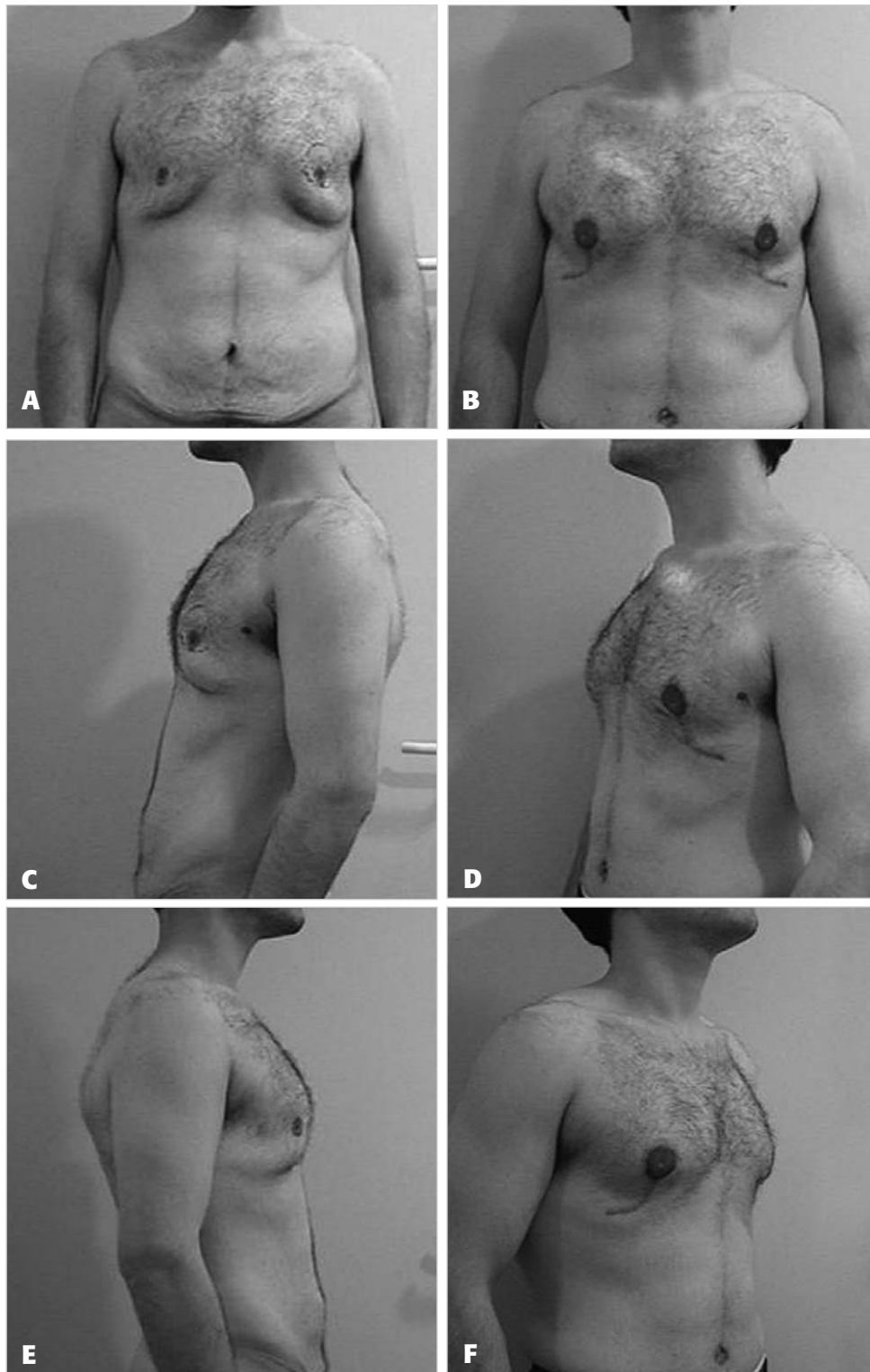


Figure 1. Example of unacceptable scarring of the anterior chest. **A, C, E,** Preoperative views of a 32-year-old man show breast deformity following massive weight loss. **B, D, F,** Postoperative views 8 weeks after a modified Le Jour mastopexy.

abdominoplasty design was made easier given the presence of a previous anterior abdominal midline scar. Although chest deformity was greatly improved by this procedure, further correction was warranted. The internipple distance was 23.5 cm and the nipples were 23 cm from the suprasternal notch, with marked skin

redundancy and unsightly lateral folds extending posteriorly (Figure 2). The patient was extremely reluctant to accept visible anterior chest scars. A posterolateral torso-plasty in association with transposition of the nipple-areola complex (NAC) through a circumareolar round-block technique was performed.

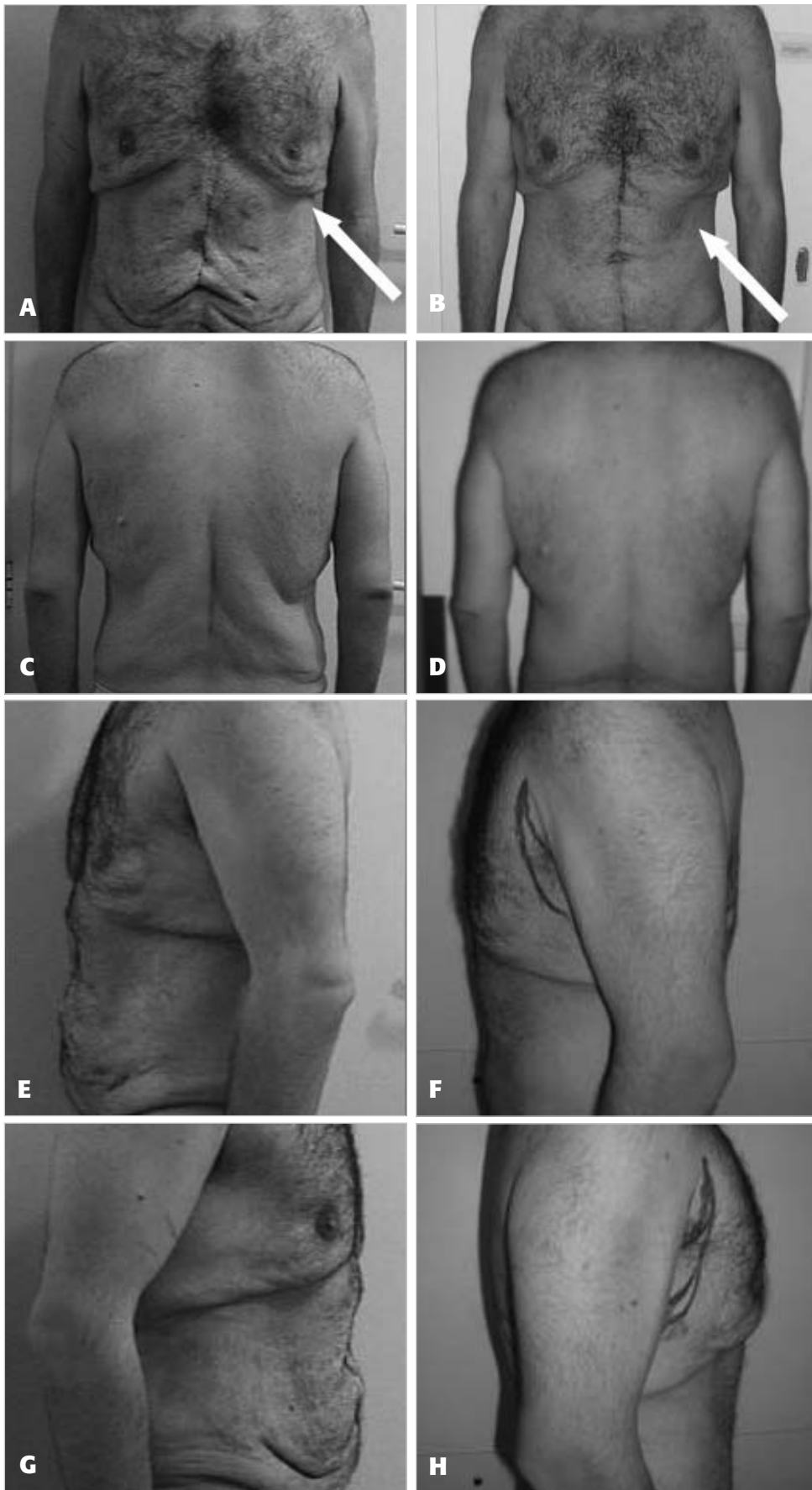


Figure 2. **A, C, E, G.** Preoperative views of a 24-year-old man following massive weight loss. **B, D, F, H.** Postoperative views 2 months after circumferential fleur-de-lys lower body lift, showing marked improvement in the contour of the chest. Left inferior chest wall; asymmetry before and after surgery is indicated by *arrows*. The asymmetry is more obvious postoperatively. Further correction was warranted (see Figure 6).

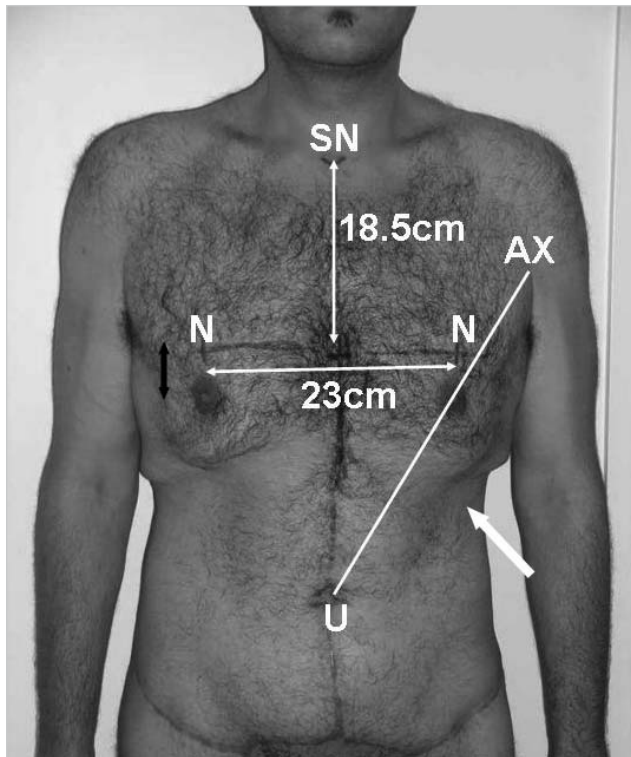


Figure 3. Determination of horizontal and vertical new nipple location coordinates. U-AX = 37 cm. Horizontal coordinate: N-N = 37×0.618 (golden number reciprocal) = 23 cm, same as the actual internipple distance of the patient. Vertical coordinate from SN: $37/2 = 18.5$ cm. Extent of required nipple lift indicated by black double-headed arrow. Lower left thoracic wall deformity indicated by arrow. (AX, anterior axillary fold apex; N, nipple; SN, suprasternal notch; U, umbilicus.)

Preoperative Markings and Surgical Technique

Determination of the new NAC position is of utmost importance preoperatively. Guidelines for determining the position of the male nipple described in the literature are vague, confusing, and sometimes conflicting.²⁵⁻²⁹ It is generally accepted that in men, the normal diameter of the NAC is 2 to 4 cm, and the average nipple to sternal notch distance is 20 cm,²⁶⁻²⁹ but little is mentioned about determining practical horizontal and vertical coordinates to position the nipples on the anterior chest. Keeping in mind the aesthetic value of the golden number ($\phi = 1.618$)³⁰ and following a study conducted on a group of male volunteers, we have concluded that the internipple distance and the vertical coordinate of the nipple plane from the suprasternal notch can be determined as a golden proportion with only one measurement—the distance from the umbilicus to the anterior axillary fold. The nipple plane was calculated to be 18.5 cm from the suprasternal notch, and the internipple distance was determined to be 23 cm (Figure 3; Table 1).

Posterolateral torsoplasty markings were performed (Figure 4) by first determining points A and B (the anterior and posterior axillary fold apex, respectively). The two points were joined by a curved line sparing the axillary hairy skin and outlining a superiorly-based flap that can be trimmed intraoperatively as required. Point C was then determined manually by bringing point C towards B

Table 1. Golden number (ϕ), golden proportion, and mathematical formula for calculation of horizontal and vertical coordinates of nipple position^a

Horizontal coordinate ^b	N-N
Vertical coordinate ^b	SN-NN
Golden number (ϕ)	1.618...
Reciprocal golden number	0.618...
N-N	Golden proportion of U-AX: $1.618 \times (N-N) = (U-AX)$
SN-NN	Golden proportion of N-N/2: $1.618 \times (N-N/2) = (SN-NN)$
Algebraic simplification	$1.618 = (U-AX)/(N-N)$ $1.618 = (SN-NN)/(N-N/2)$
$a/b = c/d$	$(U-AX)/(N-N) = (SN-NN)/(N-N/2)$
$axd = cxb$	$(U-AX) \times (N-N/2) = (SN-NN) \times (N-N)$

AX, Anterior axillary fold apex; N, nipple; N-N, Nipple-nipple distance; SN, suprasternal notch; SN-NN, suprasternal notch-horizantal nipple plane distance; U, umbilicus; U-AX, umbilicus-anterior axillary fold apex.
^aMeasurement of only the U-AX distance is required.

^bSimplified formulae: $(SN-NN) = (U-AX/2)$ and $(N-N/2) = 0.618 \times (SN-NN)$.

in an upward motion. Points A and C were then joined, making sure that the line did not extend medially to the lateral border of the pectoralis major muscle. Marking of the posterior edge of the resection was determined superiorly by the lateral border of the latissimus dorsi muscle. Both anterior and posterior markings were then curved posteriorly, joining at point D as indicated manually by the degree of back skin excision. It is essential not to locate point A so that it is noticeable on an anterior view and point B noticeable on a posterior view. As a safety measure, it is preferable to modify the markings by placing points A and B 1 to 2 cm within the axillary folds when the patient is positioned prone on the operating table with the arms abducted. Point C remained unchanged. Markings for the definitive circumareolar nipple-areola transposition were not made preoperatively because shifting of tissues in the course of the lateral torsoplasty was anticipated. Only the calculated coordinates of the vertical nipple plane and horizontal nipple position were marked.

With the patient in the prone position, incisions B-D and C-D were made, and excision of the lateral and posterior skin and subcutaneous fat was performed. Skin closure was accomplished by first securing first point C to point B followed by completing deep fascia and skin approximation. The patient was then turned and placed in the supine position with the arms abducted. Incisions A-C and A-B were made, completing the excision. At this stage of the procedure, the circumareolar nipple-areola transposition could be planned by drawing an ellipse between the existing NAC and the planned new location, the superior border of the ellipse being 1 to 1.5 cm superior to the planned nipple position. It is worth mentioning that noticeable tissue shifting did not occur at the

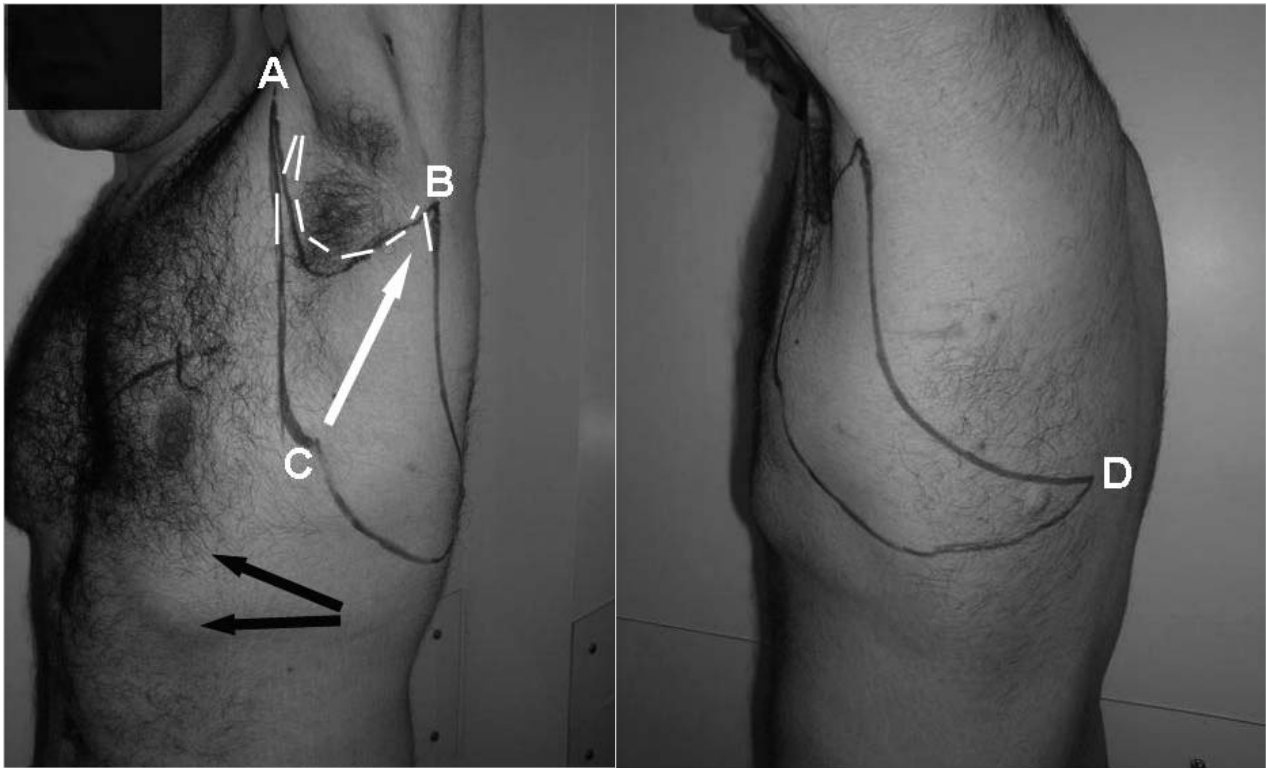


Figure 4. Preoperative markings of torsoplasty. Arrow indicates superolateral lift of lateral chest tissues. Intraoperative modification of markings indicated by broken white lines. Anteriorly projecting left costochondral cartilages with cephalad excavatum deformity indicated by black arrows.

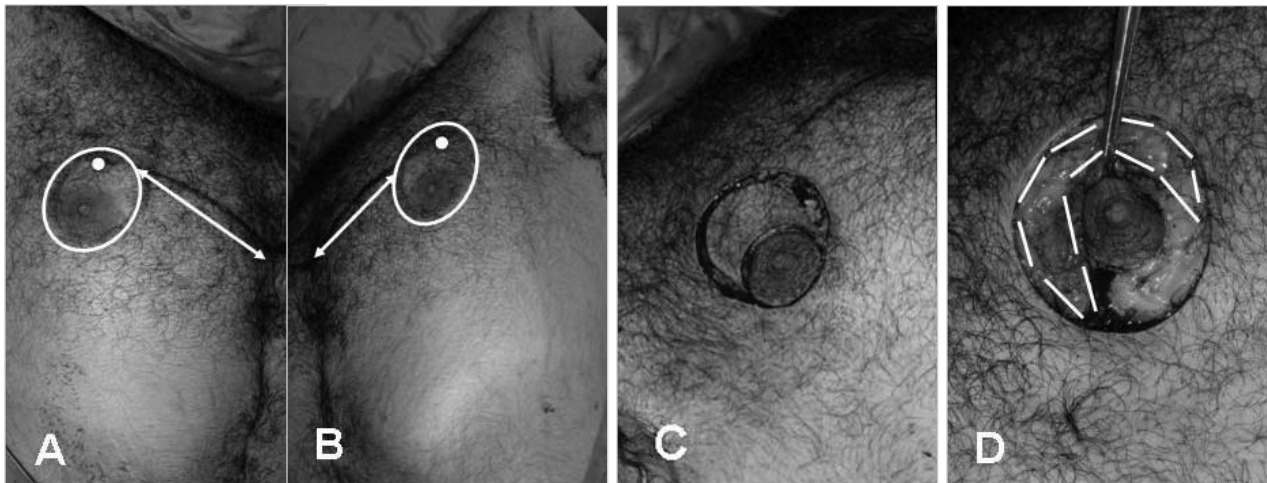


Figure 5. **A and B,** Intraoperative marking of circumareolar ellipse for nipple-areola complex transposition using the preoperatively marked nipple coordinates as guides. Note the equal distance between the medial border of the ellipse and the midline on the right and left. **C,** Skin and glandular crescent excised. **D,** Limits of glandular resection marked with white broken lines delineating an inferiorly based glandular nipple-areola pedicle.

planned new NAC location as determined by intraoperative measurements after completion of the torsoplasty. Tissue shifting occurred mainly at the existing NAC.

In this particular patient, the right nipple became more displaced laterally because of the greater degree of skin redundancy originally present on that side that required excision, and probably also because of anterior rib asymmetry that was difficult to demonstrate radiographically but was noticeable upon physical examination. Design of the periareolar resection was consequently asymmetric, while keeping the distances between the midline and the medial border of the anti-

ciated right and left periareolar incisions equal at 10 to 10.5 cm, the calculated new nipple position being at 11.5 cm. A crescent of skin and variable amounts of glandular and fat tissues were excised as indicated. Incising the dermis at the lower border of the areola was sufficient to free an inferiorly-based glandular pedicle, allowing significant superior, medial, or lateral translocation without the need of subareolar glandular undermining (Figure 5). The NAC was transposed and secured in the new position by approximating the margins of the glandular resection. Skin closure was then completed by a standard Benelli round-block technique (Figure 6).³⁰

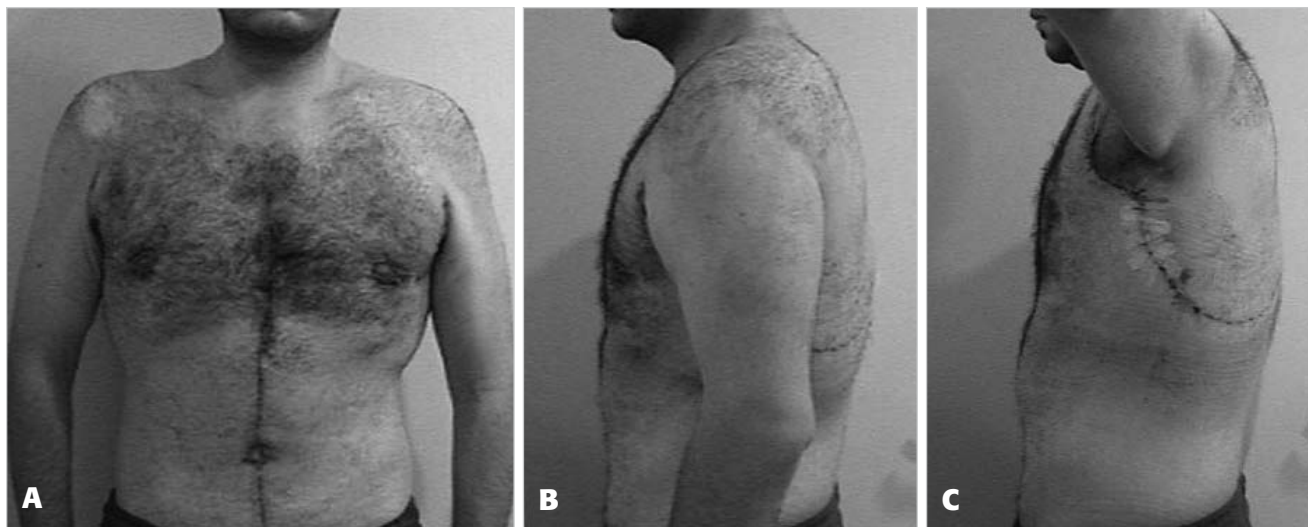


Figure 6. A-C, The immediate postoperative result was pleasing despite noticeable anterior rib deformity and asymmetry.

DISCUSSION

The male breast is a region that symbolizes manhood and strength.¹ Men in general have a very consistent body habitus, with truncal fat deposition predominantly affecting the chest, abdomen, and flanks.²⁰ Morbidly obese men have an android or central distribution of fat,⁵ with invariably enlarged and ptotic breasts.³¹ In male patients who have experienced MWL, the anterior chest has a female appearance,¹⁴ producing a significant aesthetic deformity that is commonly a source of embarrassment and shame for the afflicted individual, especially when he is required to wear tight clothing, as in a sporting event.²² Because the problem poses no functional concerns, treatment is not indicated in most cases. Surgical correction, however, is commonly performed for cosmetic and psychological reasons.³³

A wide range of excisional and lipoplasty procedures have been described and adopted by different authors for the treatment of gynecomastia.^{21,27,31,35-39} and are also applicable for correction of post-MWL breast deformities. Various incisions on and under the breast—including transareolar, periareolar, and inframammary incisions—have been used.^{24,33,40-42} The NAC can be relocated as a full-thickness graft^{28,43,44} or preserved on a deepithelialized flap.^{43,45-47} Choice of the optimal technique will ultimately depend on the degree of the deformity and on the distribution and proportion of the different components (fat and parenchyma) of the breast.⁴⁸

It must be noted, however, that after massive weight reduction, the breasts may actually decrease in size without an accompanying shrinkage of skin.⁴⁹ Resulting deformities do not fit exactly into the currently adopted gynecomastia classification, which is based on the type of required surgical correction.³³ A more useful and practical classification must be developed for MWL patients, taking into consideration issues such as fat versus glandular tissue and skin elasticity, to encompass the wide range of observed deformities.

Available surgical techniques usually result in scars that may not be aesthetically acceptable and may migrate or shift over time.^{20,50} In a patient with skin redundancy, an inverted-T mastopexy placing scars along the anterior chest can have a positive effect by eliminating the excess skin and providing more control over the position of the NAC. In some cases, the inframammary fold is fairly well defined, but the NAC complex lies well below it. In these situations, an inverted-T mastopexy with an inferior glandular nipple areolar pedicle may not be adequate, because it may result in bulkiness of the central chest. This type of patient is best managed by direct excision of the excess tissue at the level of the inframammary fold, with a free graft of the NAC. Even though the vertical scar is eliminated, scars can be more prominent with this technique.⁵¹ In some cases, excess skin can be resected by a circumareolar approach either with^{44,45,62,63} or without^{44,54,55} a purse-string suture. Redundant inelastic skin can also be removed through long obliquely-oriented anterolateral chest wall excisions in the form of a boomerang above the nipple.¹⁵

Regardless of the procedure, scar placement is an important consideration.²⁰ As a general principle, incisions outside the areola should be avoided when possible.⁵⁰ However, for post-MWL anterior chest deformities, as in some cases of gynecomastia with significant redundancy, the usual method of subcutaneous mastectomy may be inadequate,³¹ because these patients may require extensive skin resection.²⁰ In these cases, accurate scar placement helps ensure a cosmetically acceptable location, adequate resection of the tissue, and a pleasing contour.²⁰ The surgical technique must be adapted to the type of deformity and existing anterior chest wall asymmetries. Allowances must be made for the amount of redundant skin.³³ It must be kept in mind that the thorax has anterior and posterior midline zones of adherence that prevent their overlying skin from movement during weight gain and weight loss. The lateral aspect of the

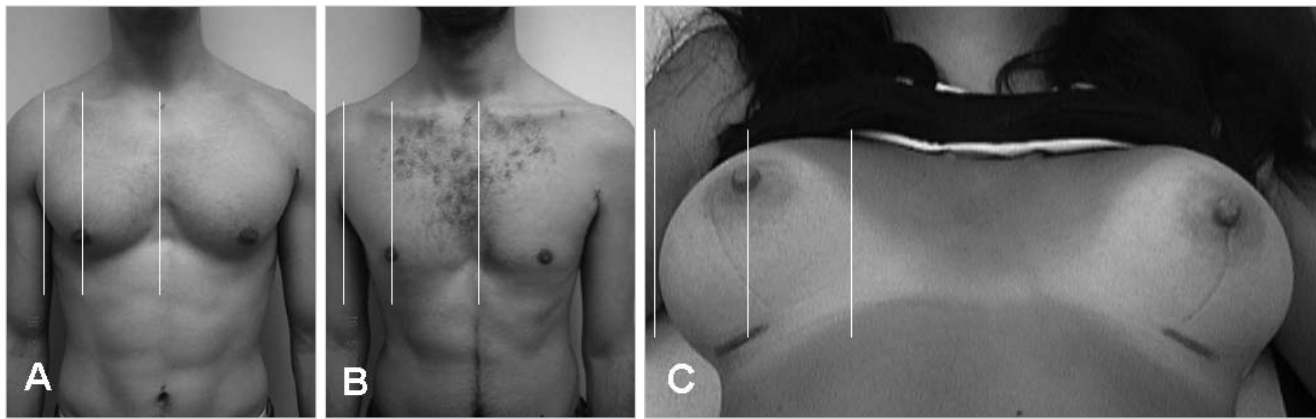


Figure 7. **A** and **B**, Position of nipple–areola complex in normal young males of different body habitus. Vertical lines define nipple position with respect to midline and acromioclavicular joint. **C**, Female breasts’ appearance with breast augmentation in supine position. Despite major lateral displacement, the nipples remain centered with respect to the mammary gland.

inframammary fold, on the other hand, is less adherent, which often results in vertical descent in this region.²⁰

It has been claimed that in men, a single-stage total body lift has technical advantages for the correction of gynecomastia with inelastic skin.¹⁵ However, it must be stressed that staging is important, and patients with a higher starting BMI are more likely to require a staged approach than those with a lower BMI. Each procedure can have an impact on adjacent areas of the body, eliminating the need for additional procedures.⁵⁵ It is preferable to perform a lower body procedure (referred to as a lower body lift, belt lipectomy, or circumferential abdominoplasty) on a male patient before upper trunk contouring. Lower body procedures often combined with lipoplasty to the chest and flanks may diminish projection and tighten the chest sufficiently so that further surgery is unnecessary.^{20,49,55} In any case, the complexity of fitting the lower body shape to the upper body shape following the sole reshaping of the lower torso by circumferential abdominoplasty, modified lower body lift, and medial thighplasty has been addressed only recently.⁵⁴ In selected patients, the procedure requested may include chest augmentation, preferably with autologous tissue, in addition to transposition of the NAC.⁵⁵

In men, the disadvantages of surgical correction of grade III and IV gynecomastia remain the visible scars on the chest wall.¹⁴ Although skin excess remains a challenge, it has been asserted that it can be satisfactorily managed without excessive prominent scarring.^{14,21,34} Individual considerations must be taken into account, and a balance must be achieved between excisional surgery and volume augmentation.⁴⁹ Factors that must be considered for the correction of grade IV postbariatric MWL deformity include BMI (before and after weight loss), the degree of NAC ptosis, amount of breast projection, hypertrophy, and skin excess, and loss of inframammary fold definition.⁴⁹ The technique we describe could be applicable for many of these patients. NAC relocation is an essential part of the technique to avoid malposition. Even for simple correction of gynecomastia, normal weight patients often complain of malpositioning

of the NAC.²⁷ Invariably, lateral displacement of the complex occurs with lateral chest lifting or torsoplasty. A similar technique has indeed been used to lateralize medially placed NAC complexes in female patients following mammoplasty.¹⁴

While the mathematical formula we have developed to determine the proper NAC position may seem confusing, it is in fact a simple and reliable approximation. Although it may seem to result in the nipples being positioned more laterally than they should, this is actually not true. In the case we have reported, the calculated internipple distance was identical to the actual preoperative distance which indeed was judged to be appropriate. The NACs had to be translocated only superiorly. The medial translocation was performed only to correct the secondary lateral displacement resulting from the torsoplasty. Nipples in both males and females are positioned laterally on the chest wall. This lateral location, however, is not appreciated in females, because the nipples are not viewed in relation to the chest wall, but rather to the mammary gland, which may be pendulous and tend to shift greatly in position (Figure 7).

CONCLUSIONS

Various designs for torsoplasty have already been described to correct skin ptosis in the subaxillary lateral chest wall in female patients and to contour the male chest following MWL.^{14,19,56} The goals of chest lifting in males are to tighten, flatten, and harmonize the surface over the frontal thoracic wall without noticeable scars in the frontal view by hiding the scars in the shadow of the arms.¹⁴ Concomitant NAC transposition has not been previously described but is, in our opinion, essential in most cases, because noticeable lateral and sometimes asymmetric shifting of the NAC is to be expected. Regardless of the technique, the critical components of male chest rejuvenation include proper placement of the NAC.⁴⁹

Moreover, despite claims that it is impossible to define the markings when the patient is lying on the operating table,¹⁴ markings for the definitive NAC circumareolar transposition cannot be made until after the

torsoplasty has been completed. However, meticulous marking of vertical and horizontal coordinates for the new nipple location with the patient in the standing position is critical. These coordinates do not shift noticeably with torsoplasty; therefore, they can be used as guidelines for definitive circumareolar markings with the patient supine and arms extended.

As with other MWL body contouring procedures, patients must understand that visible scars are unavoidable to achieve an improved appearance in clothing.⁴⁹ However, the technique we are proposing results in relatively hidden scars and avoids mutilating anterior chest scars. Most skin redundancy can be eliminated by the posterolateral torsoplasty, which at the same time achieves an upward lift of the NAC. Any necessary additional periareolar skin resection for better nipple positioning would be minor compared to the resection required without lateral torsoplasty. ▀

DISCLOSURES

The authors have no conflicts of interest with respect to the contents of this article.

REFERENCES

1. Stoff A, Reichenberger MA, Richter DF. Male breast contouring after massive weight loss. *Handchir Mikrochir Plast Chir* 2006;38:209–216.
2. Araco A, Gravante G, Araco F, Delogu V, Filingeri V, Cerveli V. Body contouring after weight loss: the plastic-bariatric surgery symbiosis. *Aesthetic Plast Surg* 2006;30:374–376.
3. Jacobs J, Schechner S, Jacobs JS. Abdominoplasty following massive weight loss. *Semin Plast Surg* 2006;20:15–23.
4. Borud LJ, Warren AG. Modified vertical abdominoplasty in the massive weight loss patient. *Plast Reconstr Surg* 2007;119:1911–1921.
5. Nemerofsky RB, Oliak DA, Capella JF. Body lift: an account of 200 consecutive cases in the massive weight loss patient. *Plast Reconstr Surg* 2006;117:414–430.
6. Rohrich RJ, Gosman AA, Conrad MH, Coleman J. Simplifying circumferential body contouring: the central body lift evolution. *Plast Reconstr Surg* 2006;118:525–535.
7. Zuelzer HB, Baugh NG. Bariatric and body-contouring surgery: a continuum of care for excess and lax skin. *Plast Surg Nurs* 2007;27:3–13.
8. Spector J, Levine S, Karp N. Surgical solutions to the problem of massive weight loss. *World J Gastroenterol* 2006;12:6602–6607.
9. Kwei S, Borud LJ, Lee BT. Mastopexy with autologous augmentation after massive weight loss: the intercostal artery perforator (ICAP) flap. *Ann Plast Surg* 2006;57:361–365.
10. Sagrillo D, Kunz S. Addressing skin redundancy after major weight loss. *Plast Surg Nurs* 2004;24:130–133.
11. Strauch B, Herman C, Rohde C, Baum T. Mid-body contouring in the post-bariatric surgery patient. *Plast Reconstr Surg* 2006;117:2200–2211.
12. Song AY, Jean RD, Hurwitz DJ, Fernstrom MH, Scott JA, Rubin JPA. Classification of contour deformities after bariatric weight loss: the Pittsburgh Rating Scale. *Plast Reconstr Surg* 2005;116:1535–1544.
13. Song, AY, O'Toole JP, Jean RD, Hurwitz DJ, Fernstrom MH, Scott JA, et al. A classification of contour deformities after massive weight loss: application of the Pittsburgh Rating Scale. *Semin Plast Surg* 2006;20:24–29.
14. Finckenstein JG, Wolf H. Chest lifting. *Aesthetic Plast Surg* 2006;30:286–293.
15. Hurwitz DJ. Single-staged total body lift after massive weight loss. *Ann Plast Surg* 2004;52:435–441.
16. Hurwitz DJ, Golla D. Breast reshaping after massive weight loss. *Semin Plast Surg* 2004;18:179–187.
17. Pascal JF, Le Louran C. Remodeling body lift with high lateral tension. *Aesthetic Plast Surg* 2002;26:223–230.
18. Bauer T, Gruber S, Todoroff B. Peri-areolar approach in pronounced gynecomastia with focus-plasty and liposuction. *Chirurg* 2001;72:433–436.
19. Cannistra C, Rodrigo V, Marmuse JP. Torsoplasty after important weight loss. *Aesthetic Plast Surg* 2006;30:667–671.
20. Examination of the massive weight loss patient and staging considerations. *Plast Reconstr Surg* 2006;117(Suppl 1):22S–30S.
21. Fruhstorfer BH, Malata CM. A systematic approach to the surgical treatment of gynecomastia. *Br J Plast Surg* 2003;56:237–246.
22. Aslan G, Tuncali D, Terzioglu A, Bingul F. Periareolar-transareolar-perithelical incision for the surgical treatment of gynecomastia. *Ann Plast Surg* 2005;54:130–134.
23. Prado AC, Castillo PF. Minimal surgical access to treat gynecomastia with the use of power-assisted arthroscopic-endoscopic cartilage shaver. *Plast Reconstr Surg* 2005;115:939–942.
24. Bracaglia R, Fortunato R, Gentileschi S, Seccia A, Farallo E. Our experience with the so-called pull-through technique combined with liposuction for management of gynecomastia. *Ann Plast Surg* 2004;53:22–26.
25. Beer GM, Budi SM, Seifert B, Morgenthaler W, Infanger M, Meyer VE. Configuration and localization of the nipple-areola complex in men. *Plast Reconstr Surg* 2001;108:1947–1952.
26. Shulman O, Badani E, Wolf Y, Hauben DJ. Appropriate location of the nipple-areola complex in males. *Plast Reconstr Surg* 2001;108:348–351.
27. Tashkandi M, Al-Qattan MM, Hassanain JM, Hawary MB, Sultan M. The surgical management of high-grade gynecomastia. *Ann Plast Surg* 2004;53:17–20.
28. Murphy TP, Ehrlichman RJ, Seckel BR. Nipple placement in simple mastectomy with free nipple grafting for severe gynecomastia. *Plast Reconstr Surg* 1994;94:818–823.
29. Beckenstein MS, Windle BH, Stroup RT. Anatomical parameters for nipple position and areolar diameter in males. *Ann Plast Surg* 1996;36:33–36.
30. Atiyeh BS, Hayek NS. Numerical expression of aesthetics and beauty. *Aesthetic Plast Surg* 2008;32:209–216.
31. Coskun A, Duzgun SA, Bozer M, Akinci OF, Uzunkoy A. Modified technique for correction of gynecomastia. *Eur J Surg* 2001;167:822–824.
32. Celebioglu S, Ertas NM, Ozdil K, Oktem F. Gynecomastia treatment with subareolar glandular pedicle. *Aesthetic Plast Surg* 2004;28:281–286.
33. Simon BE, Hoffman S, Kahn S. Classification and surgical correction of gynecomastia. *Plast Reconstr Surg* 1973;51:48–52.
34. Wiesman IM, Lehman JA Jr, Parker MG, Tantri MDP, Wagner DS, Pedersen JC. Gynecomastia: an outcome analysis. *Ann Plast Surg* 2004;53:97–101.
35. Rohrich RJ, Ha RK, Jeffrey M, Adams WP Jr. Classification and management of gynecomastia: defining the role of ultrasound-assisted liposuction. *Plast Reconstr Surg* 2003;111:909–923.
36. Freiberg A, Hong C. Apple-coring technique for severe gynecomastia. *Can J Surg* 1987;30:57–60.
37. Steele SR, Martin MJ, Place RJ. Gynecomastia: complications of the subcutaneous mastectomy. *Am J Surg* 2002;68:210–213.
38. Morselli PG. "Pull-through": a new technique for breast reduction in gynecomastia. *Plast Reconstr Surg* 1996;97:450–454.
39. Thione A, Valdatta L, Gottardi A. A modified inverted omega incision for surgical treatment of gynecomastia. *Ann Plast Surg* 2005;55:437.
40. Gioffrè Florio MA, Alfio AR, Famà F, Giacobbe G, Pollicino A, Scarfò P. Evaluation of complications and long-term results after surgery for gynecomastia (in Italian). *Chir Ital* 2004;56:113–116.
41. Cai JML, Gao X, Qian H, Pan B, Sun J. The double-ring, single-pedicle reduction plasty for gynecomastia. *Zhonghua Zheng Xing Wai Ke Za Zhi* 2002;18:46–48.
42. Filho DH, Arruda RG, Alonso N. Treatment of severe gynecomastia (Grade III) by resection of periarcolar skin. *Aesthetic Surg J* 2006;26:669–673.
43. Persichetti PBM, Casadei RM, Marangi GF, Di Lella F, Nobili AM. Gynecomastia and the complete circumareolar approach in the surgical

- management of skin redundancy. *Plast Reconstr Surg* 2001;107:948–954.
44. Botta SA. Alternatives for the surgical correction of severe gynecomastia. *Aesthetic Plast Surg* 1998;22:65–70.
45. Kornstein AN, Cinelli PB. Inferior pedicle reduction technique for larger forms of gynecomastia. *Aesthetic Plast Surg* 1992;16:331–335.
46. Brenner P, Berger A, Schneider W, Axmann HD. Male reduction mammoplasty in serious gynecomastias. *Aesthetic Plast Surg* 1992;16:325–330.
47. Teimourian B, Perlman R. Surgery for gynecomastia. *Aesthetic Plast Surg* 1983;7:155–157.
48. Oroz J, Pelay MJ, Roldan P. Gynecomastia. Surgical treatment. *An Sist Sanit Navar* 2005;28:109–116.
49. Marking and operative techniques. *Plast Reconstr Surg* 2006;117(Suppl 1):45S–73S.
50. Peled IJ. The concentric mastopexy and purse-string suture. *Plast Reconstr Surg* 1991;87:385.
51. Smoot EC III. Eccentric skin resection and purse-string closure for skin reduction with mastectomy for gynecomastia. *Ann Plast Surg* 1998;41:378–383.
52. Huang TT, Hidalgo JE, Lewis SR. A circumareolar approach in surgical management of gynecomastia. *Plast Reconstr Surg* 1982;69:35–40.
53. Peters MH, Vastine V, Knox L, Morgan RF. Treatment of adolescent gynecomastia using a bipedicle technique. *Ann Plast Surg* 1998;40:241–245.
54. Summary. *Plast Reconstr Surg* 2006;117(Suppl 1):82S–83S.
55. Silfen R, Ritz M, Southwick G. Use of pedicled local flaps for male chest augmentation and reshaping. *Plast Reconstr Surg* 2006;117:1447–1451.
56. Hunstad JP. Torsoplasty after important weight loss: discussion of flankplasty. *Aesthetic Plast Surg* 2006;30:672–674

Accepted for publication January 31, 2008.

Reprint requests: Bishara S. Atiyeh, MD, American University of Beirut, Division of Plastic Surgery, Cairo Street, Hamra, Beirut, Lebanon.

E-mail: ata@terra.net.lb.

Copyright © 2008 by The American Society for Aesthetic Plastic Surgery, Inc.

1090-820X/\$34.00

doi:10.1016/j.asj.2008.07.008
